

CHAPTER 4

MAJOR CONNECTORS

DEFINITION

The MAJOR CONNECTOR is that part of a RPD that joins the component parts on one side of the arch to those on the opposite side.¹ It is the unit of the RPD to which all other parts are directly or indirectly attached.²

FUNCTIONS

The functions of the major connector are to:

1. Join the various parts of a RPD so that the prosthesis acts as a single unit. A major connector must be rigid so that the component parts do not function independently from one another. This way, forces applied to one part of the RPD are transmitted to other parts and are dissipated by all teeth and tissues contacted, rather than just by those where the force is applied.
2. Maxillary major connectors for tooth-tissue supported RPDs provide some support, retention and direct-indirect retention(Fig. 4-1).

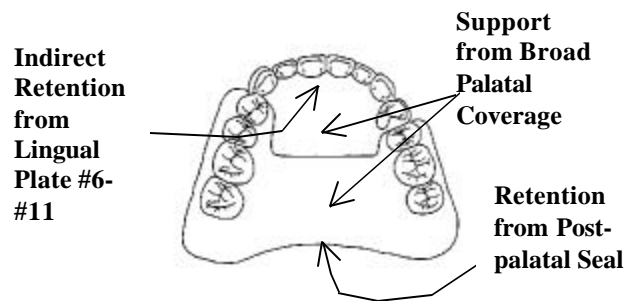


Fig. 4-1. Full palatal coverage providing some support, retention and indirect retention

3. Occasionally, in retrognathic jaw relationships, anterior occlusion and incisal guidance is incorporated into the anterior portion of the maxillary major connector (Fig. 4-2).

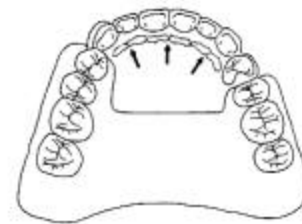


Fig. 4-2. Occlusion provided on a palatal major connector-arrows indicate areas of mandibular anterior tooth contact on the maxillary major connector

NOMENCLATURE

Major connectors are named by their location and shape. Maxillary major connectors are located on the palate. Mandibular major connectors are usually located on the lingual surface of the ridge and teeth. Rarely, mandibular major connectors are located on the labial alveolar ridge area or under the anterior part of the tongue.

Major connectors are shaped as bars and straps or plates. A BAR-SHAPED major connector is long, narrow, and thick. In cross section bars are ½ round, ½ oval or ½ pear in shape (Fig. 4-3). The thickness of a bar should be at least 6 gauge (4.11 mm) at its greatest dimension. The minimum width of a bar is 4 mm, but they must usually be wider than this for adequate rigidity.

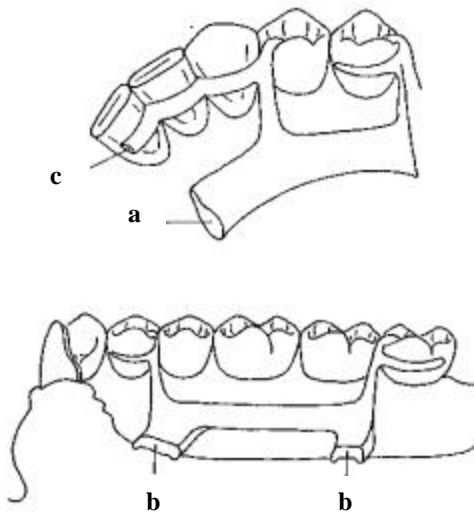


Fig. 4-3. Shapes of bars, a) ½ pear, b) ½ oval, c) ½ round

A STRAP or PLATE-SHAPED major connector is long, wide and thin (Fig. 4-4). The width of a strap or plate varies from 6 - 8 mm to the entire length of the palate. The thickest portion of straps or plates is 22 - 24 gauge (0.64-0.51 mm).

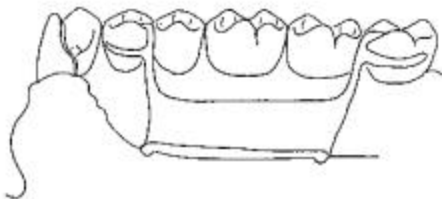


Fig. 4-4. A strap or plate

Frequently a strap or plate is added to a bar extending the major connector onto

the tooth surfaces (Fig. 4-5). This is sometimes called an APRON.

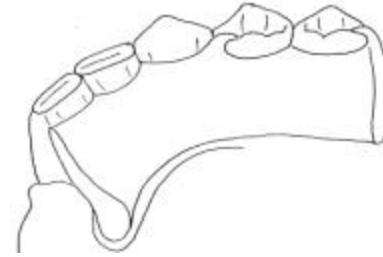

Fig. 4-5. A strap or plate added to a bar to extend the major connector onto a tooth surface

The location, width, thickness, and shape of a major connector should be determined by the dentist and RPD laboratory technician based on their knowledge of the physical properties of the alloy to be used for the framework and the anatomy of the partially edentulous arch. The more rigid the alloy, the smaller and thinner the framework may be. The bigger the arch, the thicker and wider the major connector must be to provide the necessary rigidity.

MANDIBULAR MAJOR CONNECTORS

There are six mandibular major connectors described in the literature: lingual bar, lingual plate, lingual bar with a continuous bar indirect retainer, labial bar (or plate), cingulum bar and sublingual bar. Of these, the lingual bar and lingual plate are used very frequently.^{3,4} The other mandibular major connectors are seldom indicated, or are advocated by few practitioners.

In this section the indications, contraindications, advantages and disadvantages of each mandibular major connector is listed and the design of each major connector and location of its borders illustrated in the accompanying figures.

LINGUAL BAR

SYNONYMS: ALVEOLAR BAR

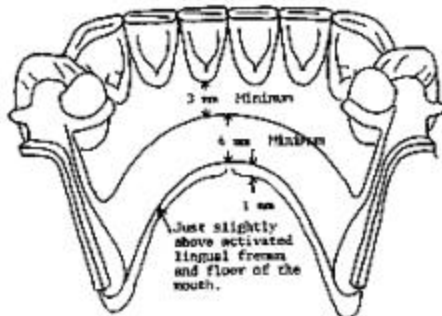


Fig. 4-6. LINGUAL BAR

Indications:

1. The lingual bar is the mandibular major connector of choice if sufficient bracing and indirect retention can be provided by clasps and indirect retainers; and if future additions of prosthetic teeth to the framework to replace extracted natural teeth are not anticipated.
2. Diastemas or open cervical embrasures of anterior teeth .
3. Overlapped anterior teeth.

Contraindications:

1. Less than 8 mm between the marginal gingiva and the activated lingual frenum and floor of the mouth.
2. Only a few remaining anterior teeth which must be contacted to provide a reference for fitting the framework and indirect retention.
3. Lingually inclined teeth.
4. An undercut lingual alveolar ridge which would result in an excessive space between

the bar and the mucosa. (Fig. 4-7).

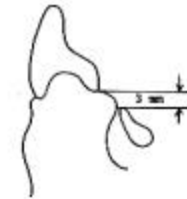

Fig. 4-7. An undercut lingual alveolar ridge contraindicates the use of a lingual bar because of the excessive space between the bar and mucosa

5. A parallel or sloped anterior lingual alveolar contour in a distal extension RPD where the bar may rotate into the tissues as the denture base moves toward the residual ridge (Fig. 4-8).

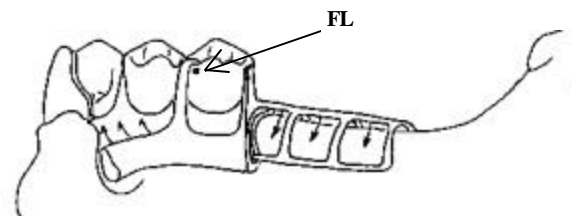


Fig. 4-8. A lingual bar is contraindicated if the shape of the lingual alveolar ridge will result in the bar rotating into the tissue as the base moves toward the tissue around the fulcrum line (FL)

Advantages:

1. Covers a minimum of surface area of teeth and tissues therefore the potential for caries, periodontal problems and mucositis caused by plaque being held in contact with teeth and tissues is minimal.
2. Patients prefer lingual bar to lingual plate, probably because it is relatively small, inconspicuously located and minimally interferes with function.^{5,6}

3. Esthetic.

Disadvantages:

1. Not as rigid as the lingual plate, sublingual bar or lingual bar with continuous bar indirect retainer.
2. Difficult to add additional prosthetic teeth to framework.
3. Framework goes from thick (at the minor connectors) to thin (at the bar) to thick again which is metallurgically and structurally complicated. The result may be weak areas in the casting with the potential to fracture.

3. Undercut or parallel lingual alveolar ridge when the superior edge of a lingual bar can not be located in close contact with the mucosa and still be at least 3 mm inferior to the marginal gingiva.
4. Distal extension RPDs with parallel or sloped lingual alveolar ridges where a lingual bar would rotate into the ridge when the base area rotates tissueward.
5. Mandibular tori or exostosis which must be covered by the RPD because they can not be surgically removed or avoided in the RPD design. Relief is provided between the torus or exostosis and the framework.

LINGUAL PLATE

SYNONYMS: LINGUOPLATE, LINGUAL APRON, CLOSED KENNEDY MAJOR CONNECTOR.

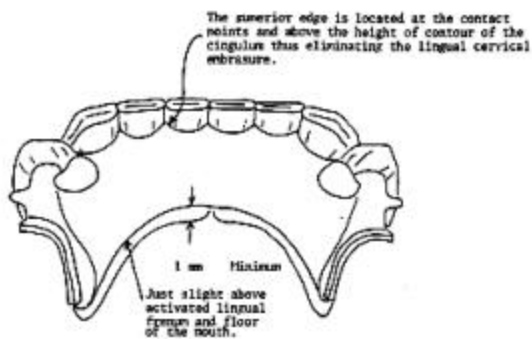


Fig. 4-9. LINGUAL PLATE

Indications:

1. Less than 8 mm between the marginal gingiva and the activated lingual frenum and of the mouth.
2. Only a few remaining anterior teeth which must be contacted to provide a reference for fitting the framework and indirect retention.

Contraindications:

1. A lingual bar may be used.
2. Overlapped anterior teeth where the undercuts in the area of the superior edge of the plate can not be removed (Fig. 4-10). Frequently this criteria can not be met and a lingual plate which will have small gaps between the superior edge of the plate and the teeth must be used.

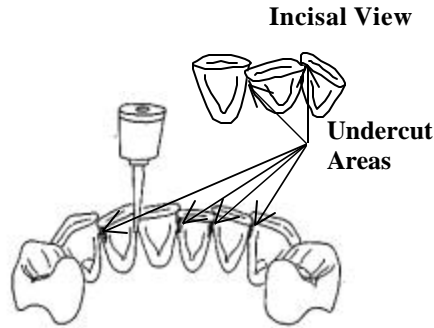


Fig. 4-10. Undercuts in the area of the superior edge of a lingual plate must be removed to allow contact of the plate with the teeth

3. Lingually inclined teeth.
4. Diastemas, unless the lingual plate can have slots in it to avoid the display of metal (Fig. 4-11).

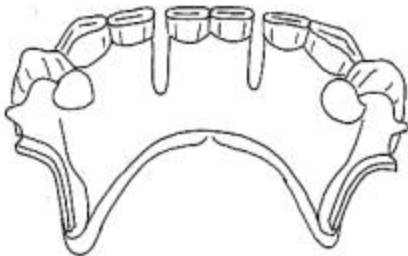


Fig. 4-11. Placing slots in a lingual plate will prevent the metal showing through diastemas

5. Open cervical embrasures where the plate would be visible (Fig. 4-12). A lingual bar with continuous bar indirect retainer or a labial bar should be considered.

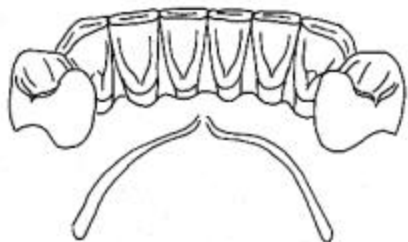


Fig. 4-12. Open cervical embrasures contraindicate the use of a lingual plate

Advantages:

1. More rigid than a lingual bar.
2. Metallurgically and structurally simple.
3. Easy to add additional prosthetic teeth to framework.
4. May prevent supraeruption of the teeth it contacts.

Disadvantages:

1. Covers more tooth and tissue surface than lingual bar.
2. May be more noticeable to patient than lingual bar.
3. May cause flaring of incisors if it contacts their cingula as the base area rotates tissueward.

LINGUAL BAR WITH CONTINUOUS BAR INDIRECT RETAINER

SYNONYMS: KENNEDY BAR, SPLIT LINGUAL BAR, DOUBLELINGUAL BAR

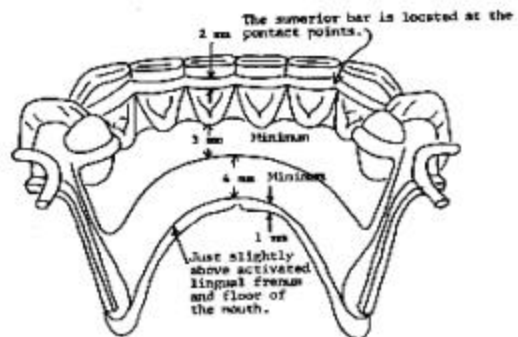


Fig. 4-13. LINGUAL BAR with CONTINUOUS BAR INDIRECT RETAINER

Indications:

1. Situations where the major connector must contact the natural teeth to provide bracing and indirect retention and there are open cervical embrasures which contraindicate the use of a lingual plate. There must be

adequate space for the lingual bar portion of the major connector.

Contraindications:

1. Where a lingual bar or lingual plate will suffice.
2. Any contraindication for a lingual bar.
3. Any contraindication for a lingual plate except open cervical embrasures.
4. Diastemas.

Advantages:

1. More rigid than lingual bar.
2. Covers less tooth and tissue surface than lingual plate.

Disadvantages:

1. Very complex design.
2. May be objectionable to patient because there are four edges exposed to the tip of the tongue.

LABIAL BAR (OR PLATE)

SYNONYMS: None

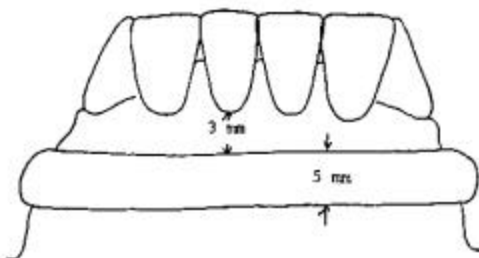


Fig. 4-14. LABIAL BAR

Indications:

1. Lingually inclined teeth preventing the use of a lingual mandibular major connector.
2. Lingual tori or exostoses which can not be removed surgically, avoided in the RPD design, or covered by

the framework with adequate relief.

3. A lingual major connector can not be used because of the slope or undercut of the lingual alveolus.
4. The patient can not tolerate a lingual major connector.
5. Diastemas and open cervical embrasures contraindicating a lingual plate.

Contraindications:

1. A lingual major connector may be used.
2. Facial tori or exostoses.
3. The facial alveolar ridge is undercut.
4. High facial muscle attachments which would result in less than 3 mm of space between the superior edge of the labial bar and the marginal gingiva of the teeth.

Advantages:

1. Can be used where lingual major connector can not

Disadvantages:

1. A labial major connector is longer than a lingual major connector and, therefore, must be wider and/or thicker or larger to provide the necessary rigidity.
2. A labial major connector may be visible when the patient smiles and it may distort lip contour resulting in poor esthetics.
3. Difficult to add prosthetic teeth to framework.

CINGULUM BAR

SYNONYMS: None

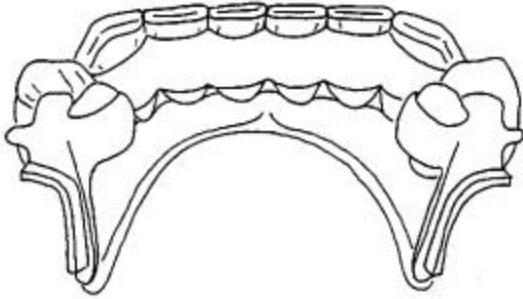


Fig. 4-15. CINGULUM BAR

Indications:

1. Height of activated lingual frenum and floor of the mouth at the same level as marginal gingiva.
2. Inoperable tori or exostoses at the same level as the marginal gingiva.
3. Severely undercut lingual alveolus
4. Concern that a major connector traversing the gingival sulcus will cause a periodontal problem.
5. Considerable gingival recession.

Contraindications:

1. When a simpler major connector may be used.
2. Diastemas and open cervical embrasures where the metal will show.

Advantages:

1. Can be used where lingual bar and lingual plate can not.
2. Does not traverse the marginal gingiva or overlay the lingual alveolus.
3. Easy to add prosthetic teeth to framework.

Disadvantages:

1. Must be bulky to have sufficient rigidity and thus may be objectionable to the patient.

SUBLINGUAL BAR

SYNONYMS: None


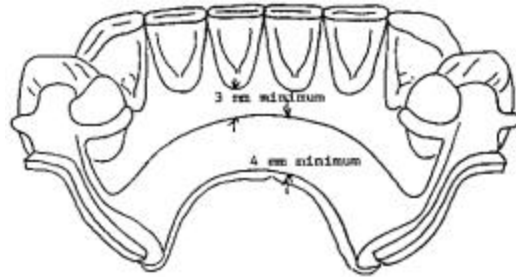


Fig. 4-16. SUBLINGUAL BAR

Indications:

1. Bracing and indirect retention can be provided by clasps and indirect retainers and future additions of prosthetic teeth to the framework are not anticipated.
2. Severely undercut lingual alveolar ridges.
3. Distal extension RPD situations with sloped or parallel lingual alveolar ridges where a lingual bar would rotate into the lingual alveolus as the base area rotates tissue ward.
4. Diastemas and open cervical embrasures of anterior teeth.
5. Overlapped anterior teeth.
6. Intolerance to other lingual major connectors.

Contraindications:

1. Where a lingual bar or lingual plate will suffice.
2. Situations where bracing and/or indirect retention must be provided by contact of the major connect with the teeth.
3. Situations where future additions of prosthetic teeth to the framework are anticipated.

Advantages:

1. Sublingual bar does not contact anterior teeth or lingual alveolus.
2. More esthetic than other lingual major connectors because of its location.
3. More rigid than lingual bar because bulk of metal is horizontal rather than vertical.

Disadvantages:

1. Requires border molded impression of floor of mouth for accurate placement of major connector.
2. Difficult to add prosthetic teeth to framework.
3. Most patients prefer a lingual plate to a sublingual bar.⁵

MAXILLARY MAJOR CONNECTORS

The terminology for, and design of, maxillary major connectors is less standardized than for mandibular major connectors. There are six maxillary major connector designs in the literature: palatal strap, palatal plate, complete palatal coverage, anteroposterior type, U-shaped and palatal bar. The palatal plate and complete palatal coverage major connectors have two distinct designs.

In this section the indications, contraindications, advantages and disadvantages of each maxillary major connector is listed and the design of each major connector and the location of its borders illustrated in the accompanying figures.

PALATAL STRAP

SYNONYMS: PALATAL PLATE, MIDDLE PALATAL STRAP OR PLATE

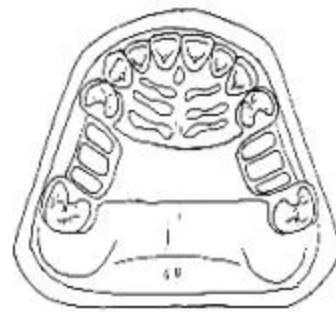


Fig. 4-17. PALATAL STRAP

Indications:

1. A Class III or Class III mod. I P partially edentulous arch.

Contraindications:

1. Tooth-tissue supported RPD.
2. Palatial torus.
3. Extremely long tooth supported edentulous space (A-P major connector would be better because it would cover less palatal tissue.)

Advantages:

1. Very simple design.
2. Posterior border is well anterior to the hamular notch-vibrating line.
3. Anterior border is posterior to rugae ("playground of the tongue").
4. Very few metal-tissue edges.

Disadvantages:

1. Covers a considerable portion of the palate.

PALATAL PLATE

SYNONYMS: BROAD PALATAL STRAP OR PLATE, POSTERIOR PALATAL STRAP OR PLATE, BROAD PALATAL MAJOR CONNECTOR

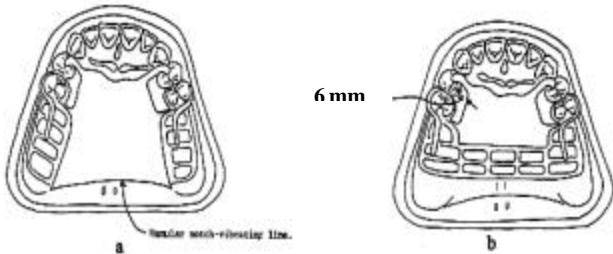


Fig. 4-18. PALATAL PLATE, a) Design I - all metal, b) Design II - metal-plastic

Indications:

1. A Class I or Class II partially edentulous arch.

Contraindications:

1. A tooth supported edentulous space.
2. A palatal torus.

Advantages:

1. Support is provided by contact of the major connector with the denture bearing foundation of the palate.
2. Fairly simple design.

Disadvantages:

1. Covers a considerable portion of the palate.
2. DESIGN I presents the following difficulties:

- a) The hamular notch-vibrating line area must be located on the master cast.
- b) Difficult to adjust the metal-tissue contact.
- c) Difficult to reline the metal portion of the palatal contact.

DESIGN II presents the following difficulty:

- a) Difficult to blend the thickness of the metal (1 mm)-plastic (3 mm) junction.
3. The anterior border is frequently located in the rugae.

COMPLETE PALATAL COVERAGE

SYNONYMS: FULL PALATAL COVERAGE, COMPLETE (FULL) PALATAL PLATE OR STRAP

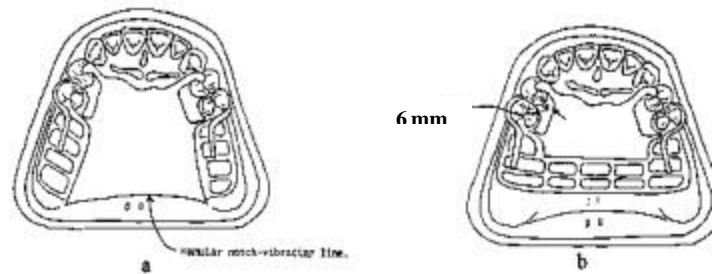


Fig. 4-19. COMPLETE PALATAL COVERAGE, a) Design I - all metal, b) Design II - metal-plastic

Indications:

1. A Class I partially edentulous arch where maximum utilization of the

palate is indicated for support, bracing, retention and direct-indirect retention.

metal-tissue contact.

c) Difficult to reline the metal portion of the palatal contact.

Contraindications:

1. When less than complete palatal coverage is necessary and there are sufficient remaining natural teeth to use a palatal plate or strap major connector.

3. Design II presents the following difficulty:
 - a) Difficult to blend the thickness of the metal (1 mm)-plastic (3 mm) junction.

Advantages:

1. Maximum support, retention, bracing and direct-indirect retention from the palate.
2. Fairly simple design.
3. Few metal tooth edges.
4. Easy to add prosthetic teeth to framework.
5. Can be easily converted to an interim complete denture.

ANTERIOR-POSTERIOR TYPE

SYNONYMS: A-P TYPE, RING-SHAPED, DOUGHNUT-SHAPED, CLOSED HORSESHOE, CIRCULAR

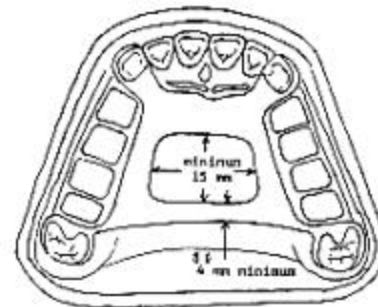


Fig. 4-20. A-P TYPE

Indications:

Disadvantages:

1. Covers more tooth and tissue surface than any major connector.
2. Design I presents the following difficulties:
 - a) The hamular notch-vibrating line area must be located on the master cast.
 - b) Difficult to adjust the

1. Class III or Class III mod 1 P partially edentulous arch with a long span edentulous space(s).
2. Class I or class II partially edentulous arch where adequate support, retention, bracing, and direct-indirect retention may be obtained from contact of the denture base with the ridge and the

contact of the framework with the palate.

3. An inoperable palatal torus.
4. A RPD replacing anterior teeth.

Contraindications:

1. Where the palatal opening will be less than 15 mm anteroposteriorly or mediolaterally.
2. Where support, retention, bracing, and direct-indirect retention from the palate is required.
3. Where a major connector with a simpler design may be used.

Advantages:

1. Covers a minimum of palatal tissues.

Disadvantages:

1. Very complex design.
2. A lot of metal-tissue edges.
3. The posterior palatal bar or strap frequently does not fit the palate closely.
4. The anterior border is frequently located in the rugae.
5. The posterior border is frequently located in the hamular notch-vibrating line area.

U-SHAPED

SYNONYMS: ANTERIOR PALATAL STRAP, HORSESHOE, OPEN RING, OPEN DOUGHNUT

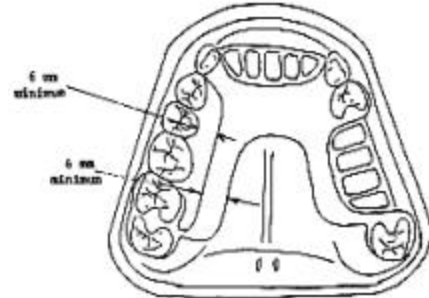


Fig. 4-21. U-SHAPED

Indications:

1. A Class IV partially edentulous arch.
2. A Class III or Class III mod 1 P partially edentulous arch with an anterior edentulous space, where cross-arch force distribution is not important.
3. A partially edentulous arch with an inoperable palatal torus.

Contraindications:

1. Where support, retention, bracing, and direct-indirect retention from the palate is necessary.
2. Where cross-arch force distribution is necessary.

Advantages:

1. Minimal coverage of the palate.
2. Fairly simple design.
3. Fewer metal-tooth or tissue edges than the A-P design.

Disadvantages:

1. Not as rigid as other maxillary major connectors. Rigidity may be increased by having the metal in the vertical and horizontal planes and is probably adequate, particularly with cast chromium alloy frameworks (Fig. 4-22).

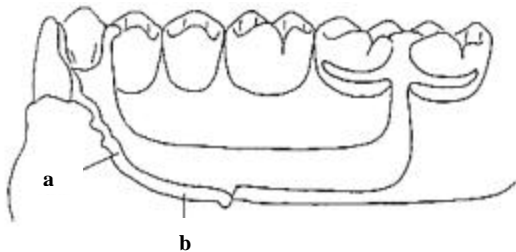


Fig. 4-22. Rigidity of a major connector is increased by having the metal on two planes, a) vertical plane, b) horizontal plane

POSTERIOR PALATAL BAR

SYNONYMS: NONE

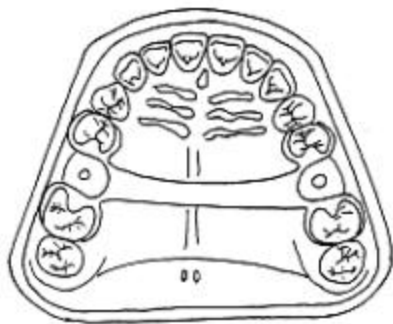


Fig. 4-23. POSTERIOR PALATAL BAR

Indications:

1. Rarely if ever indicated. Possibly a very short (1-2 tooth) posterior tooth supported edentulous space.

Contraindications:

1. Palatal torus.

2. Edentulous space larger than 1-2 teeth.

Advantages:

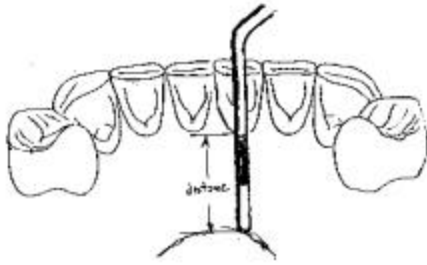
1. Minimal palatal coverage.

Disadvantages:

1. Must be bulky to be rigid and is usually objectionable to patient.⁶

LOCATING MAJOR CONNECTOR BORDERS

The location of the borders of the various major connectors in relation to the teeth and soft tissues are identified on the diagrams of the major connectors. Most of the locations can be measured directly on a cast of the arch. But the location of the inferior border of lingual bars and plates, and the posterior border of maxillary major connectors in the hamular notch-vibrating line area are related to movable tissue landmarks which can not be correctly identified from the anatomy of a cast. These landmarks must be identified in the mouth either by making measurements from an anatomic landmark (such as the marginal gingiva of anterior teeth for lingual bars and plates (Fig. 4-24), or by marking the landmark with an indelible pencil line in the mouth (such as the vibrating line) prior to making the impression for a diagnostic or master cast.



a

10. Depth of Activated Lingual Frenum and Floor of Mouth
- | | | | |
|----------|------------|------------|----------|
| | Right | Anterior | Left |
| Molar NA | Premolar E | Premolar E | Molar NA |
11. Shape of Lingual Alveolus
- | | | | |
|----------------|-----------------|----------|-----------------|
| | Right | Anterior | Left |
| Molar undercut | Premolar sloped | sloped | Premolar sloped |
| | | | Molar undercut |

b

Fig. 4-24. Evaluating mouth floor depth, a) measuring the distance from the lingual gingival margins to the activated lingual frenum and floor of the mouth using a periodontal probe, b) the measurements are recorded on the clinical form “Evaluation of the Mouth for Partial Dentures” for further use when designing an RPD and when outlining an RPD framework on a master cast

Maxillary major connector borders which traverse the arch should cross the palate at a right angle to the midline suture or through the valley between rugae (Fig. 4-25). Changes in anteroposterior location are made on the vertical slopes of the palate. If a rugae must be traversed it is crossed abruptly. The rationale for this is to hide the borders of major connectors from the tongue as much as possible.

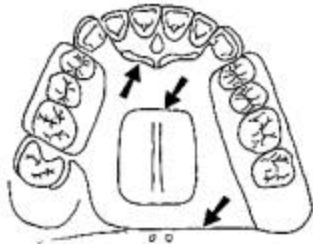


Fig. 4-25. The borders of a maxillary major connector cross the palate at right

CONTACT OF THE MAJOR CONNECTORS WITH THE TISSUES

Mandibular

The superior edge (1-2 mm) of mandibular major connectors should contact the teeth or tissues to prevent a space which would allow food impaction and accumulation and/or would be noticeable to the patient. The major connector below this contact area should be relieved to prevent contact of the framework with the teeth and/or tissues (Fig. 4-26). The amount of relief depends on the amount of anticipated tissue ward movement of the RPD plastic base.

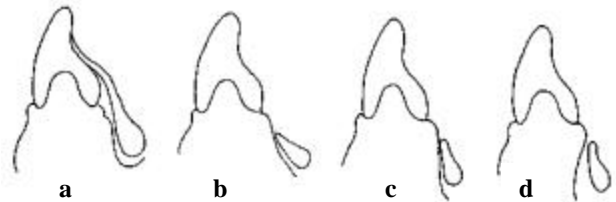


Fig. 4-26. The superior edge of mandibular major connectors contacts the teeth or mucosa and the inferior portion is relieved, a) the amount of relief depends on the shape of the lingual alveolus, b) sloped - no relief necessary, c) parallel - minimum relief, d) undercut - parallel block-out.

Maxillary

Maxillary major connectors contact the palate. They are relieved from contact only in areas of tori, hard palatal sutures, or other areas where the mucosa is very thin. The edges of maxillary major connectors which are

exposed to the tongue are **BEADED** to insure their contact with the mucosa (Fig. 4-27). The bead is approximately 1.0 mm wide and deep. It should be slightly shallower over the midline suture or other areas where the mucosa is very thin. The bead seals the metal-tissue junction preventing food and debris from being forced under the major connector as the patient swallows. The bead is necessary to compensate for the dimensional inaccuracies of the materials and techniques used to make RPDs, such as: impression materials, cast materials, the duplication process, cast alloys, finishing and polishing the framework, etc. The bead also increases the rigidity of the framework, identifies where to finish the metal, and creates a bulk of metal at the border so that the edges may be thinned to blend in with the tissues so they will be less noticeable to the patient.⁸

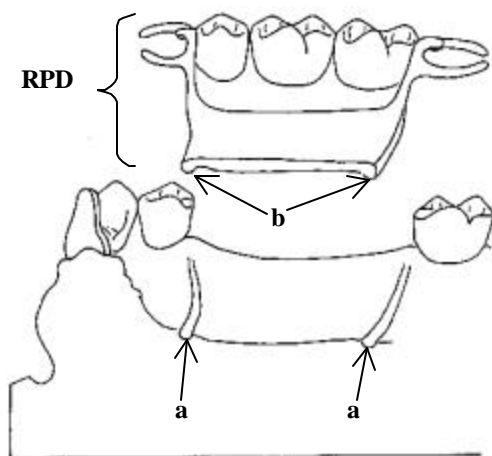


Fig. 4-27. Exposed edges of maxillary major connectors are beaded, a) the bead line scribed on the master cast, b) the resultant metal bead on the tissue surface of the major connector.

FINISH OF THE SURFACES OF MAJOR CONNECTORS

The **POLISHED SURFACE** (side away from the teeth and tissues) of RPD frameworks is finished smooth with rubber wheels and highly polished.

The **TISSUE SURFACE** (side next to the teeth and tissues) of mandibular RPD frameworks is finished smooth with rubber wheels and highly polished. The tissue surface or maxillary RPD framework is only lightly smoothed with rubber wheels and is not polished since this surface must contact the mucosa of the palate.

SELECTION OF THE MAJOR CONNECTOR

The selection of the major connector to be used for a RPD depends on many factors and is discussed in *Designing Removable Partial Dentures*.

REFERENCES

1. The glossary of prosthodontic terms. 6th ed. St. Louis, C V Mosby, 1994.
2. Henderson D, McGivney G P, Castleberry D J. McCracken's removable partial prosthodontics. 7th ed. St. Louis: C V Mosby,
3. Henderson D. Major connectors for removable partial dentures: design and function. *J. Prosthet Dent* 1973; 30:532-48.
4. Ward J E., Kazanoglu A., Burns D.R.: Survey of major connector usage in a dental school, in press.
5. Hansen C A, Campbell D J. Clinical comparison of two

- mandibular major connector designs: the sublingual bar and the lingual plate. *J Prosthet Dent* 1985; 54:805-809.
6. Campbell L D. Subjective reactions to major connector designs for removable partial dentures. *J Prosthet Dent* 1977; 37:507-16.
 7. Wagner A G, Traweek F C. Comparison of major connectors for removable partial dentures. *J Prosthet Dent* 1982; 47:242-45.
 8. Stratton R V, Wiebelt F J. A atlas of removable partial denture design. Chicago: Quintessence, 1988:37.