



THE NEUTRAL ZONE REVISITED: FROM HISTORICAL CONCEPTS TO MODERN APPLICATION

David R. Cagna, DMD, MS,^a Joseph J. Massad, DDS,^b and Frank J. Schiesser, DDS^c

University of Tennessee Health Science Center, College of Dentistry, Memphis, Tenn; Tufts University School of Dental Medicine, Boston, Mass; University of Texas Health Science Center, Dental School, San Antonio, Tex; Temple University School of Dentistry, Philadelphia, Pa

Providing complete denture therapy to patients with atrophic residual alveolar ridges is challenging. Because these patients suffer ongoing diminution of the denture foundation, modern approaches often involve dental implant therapy as a means of improving the denture foundation and supplementing the mechanics of prosthesis support, retention, and stability. Regardless of implant availability, physiologically optimal denture contours and physiologically appropriate denture tooth arrangement should be achieved to maximize prosthesis stability, comfort, and function for patients. This article presents historical perspectives on the arrangement of denture teeth in the facial-lingual dimension and the contouring of complete denture polished surfaces. Additionally, a modern clinical technique is presented for the physiologic registration of denture tooth positions and denture base contours. Information gained may then be incorporated into definitive prostheses in an effort to achieve successful complete denture therapy. (*J Prosthet Dent* 2009;101:405-412)

Practical objectives of complete denture therapy for patients with severely reduced residual alveolar ridges include the placement of functional and esthetic dentition substitutes and the replacement of associated dental supporting structures. In so doing, the prostheses often occupy a substantial volume within the edentulous oral cavity. The ideal 3-dimensional (3-D) location of this volume has historically been the subject of much debate. The therapeutic challenges associated with designing complete dentures to optimally occupy the edentulous space are substantial in the light of the aggressive and progressive changes that accompany edentulism^{1,2} and the functional dynamics that define the oral cavity.³

In addition to simply replacing

missing oral tissues, complete dentures serve to structurally redefine true spaces and potential spaces within the oral cavity. Regardless of the fabrication technique used, functionally inappropriate denture tooth arrangement or physiologically unacceptable denture base volume or contour have been implicated in poor prosthesis stability and retention,³⁻⁸ compromised phonetics,^{9,10} inadequate facial tissue support,¹⁰ inefficient tongue posture and function,¹¹ and hyperactive gagging.¹²⁻¹⁵

Directives provided for optimal facial-lingual arrangement of posterior denture teeth have varied dramatically over the profession's long history of complete denture therapy. As stated previously, the concept that posterior denture teeth should be arranged to

occupy the position of their natural tooth predecessors has been put forward.^{9,16-20} Others have suggested that posterior denture teeth should be arranged directly over the crest of the edentulous ridge.²¹⁻²⁵ Weinberg³ suggested that buccal cusps and central fossae of mandibular posterior denture teeth should be arranged directly over the crest of the edentulous residual ridge. Pound^{26,27} recommended that the lingual surfaces of mandibular posterior denture teeth should occupy an area bounded by 2 lines originating from the mesial surface of the mandibular canine and extending posteriorly to the lingual and buccal aspects of the retromolar pad. This area has been called Pound's Triangle.²⁸ A subtle modification of Pound's concept was discussed by Halperin et

^aProfessor, Department of Restorative Dentistry; Director, Advanced Prosthodontics Program, University of Tennessee Health Science Center, College of Dentistry.

^bDirector, Removable Prosthodontics, Scottsdale Center for Dentistry, Scottsdale, Ariz; Associate Faculty, Tufts University School of Dental Medicine; Adjunct Associate Faculty, Department of Prosthodontics, University of Texas Health Science Center, Dental School.

^cFormer Clinical Professor and Guest Lecturer, Department of Prosthetic Dentistry, Temple University School of Dentistry



al.²⁹ The authors suggested that the lingual surfaces of mandibular posterior denture teeth should occupy an area bounded by 2 lines originating at the mesial surface of the mandibular canine, one line extending posteriorly to the lingual border of the retromolar pad and the other extending posteriorly, passing through the central aspect of the retromolar pad.

The neutrocentric concept requires that posterior mandibular denture teeth be arranged to occupy as central a location as possible, relative to the denture foundation, without disturbing adequate tongue function.^{30,31} This tooth arrangement is said to facilitate mandibular denture stability during occlusal loading. el-Gheriani³² recommended that posterior maxillary denture teeth should be arranged to satisfy specific mathematical formulae based on natural tooth intercanine width. Lammie³³ argued that in aging patients, mandibular posterior denture teeth should be arranged over the buccal shelf to provide increased tongue space and to facilitate the development of vertical facial denture polished surfaces, against which an effective facial seal can be achieved and maintained.

Wright et al¹¹ believed that posterior mandibular denture teeth should be arranged directly over the center of the denture stress-bearing area. This location may not correlate with the crest of the edentulous ridge, particularly in the presence of severe ridge atrophy. Martone³⁴ recommended that facial cusps of mandibular first molar denture teeth should be arranged directly over the crest of the edentulous ridge. Lingual cusps of the other mandibular posterior denture teeth should correspond to a line extending from the mesial aspect of the canine denture teeth to the facial side of the retromolar pads. This line should curve in the vertical plane to correspond to the curvature of the mandibular edentulous ridge. Campbell³⁵ stated that posterior denture teeth should be so placed that a line drawn through the long axis of the tooth will pass

through the crests of the maxillary and mandibular ridges. When viewed in coronal cross-section, mandibular posterior denture teeth should be arranged slightly lingual to the crest of the edentulous ridge, while the maxillary posterior denture teeth should be arranged slightly buccal to the edentulous ridge.

Of particular interest is use of the neutral zone^{36,37} to guide posterior denture tooth arrangement and denture base contouring. Historically, different terminology has been loosely associated with this concept, including dead zone,³⁸ stable zone,⁶ zone of minimal conflict,³⁹ zone of equilibrium,⁴⁰ zone of least interference,⁴¹ biometric denture space,¹⁷ denture space,⁴² and potential denture space.⁴³ To define the neutral zone, consideration must be given to the potential denture space; that space in the edentulous mouth vacated by the natural dentition and dental supporting tissues and bounded by the tongue medially and the lips and cheeks laterally. The neutral zone resides within this potential denture space. More specifically, the neutral zone is that region where forces imposed by the tongue directed outward are neutralized by inwardly directed forces originating from the cheeks and lips during normal neuromuscular function.⁴⁴

In general, boundary conditions that define the neutral zone are developed through muscular contraction and relaxation during the various functions of mastication, phonation, deglutition, and facial expression. These neuromuscular forces vary in magnitude and direction in different areas of the oral cavity, in different individuals, and at different periods of life.⁴⁴ The trajectory of force applications to prosthetic surfaces will either serve to stabilize or dislodge the complete dentures.^{11,34,45} When the polished surface contours of the complete dentures conform to the anatomical shape and function of the tongue, lips, and cheeks, prosthesis stability and retention may be facilitated, rather than disrupted. In the

passive state, the weight and natural posture of the tongue, lips, and cheeks bearing on optimally contoured polished denture surfaces may facilitate prosthesis retention and stability.

To provide complete dentures that reside within the theoretically stabilizing boundary conditions of the neutral zone, careful attention must be given to the dynamic physiologic and functional nature of the edentulous oral cavity. Clinicians must understand, identify, induce, and record the neuromuscular dynamics of the functioning oral tissues using a single static registration. Once accomplished, this information can then be applied to the 3-D construction of the definitive prosthesis.

As detailed by Beresin and Schiesser,⁴⁴ a modeling plastic impression compound clinical registration made on specially designed record bases was used to define the neutral zone. Next, laboratory procedures incorporating impression-generated matrices⁴⁶ were accomplished to facilitate denture tooth arrangement within the registered neutral zone. Upon completion, wax trial dentures were placed and an additional impression procedure was performed using either zinc oxide and eugenol paste or tissue-conditioning material. This impression, an external impression, was made on the facial, lingual, and palatal surfaces of the trial dentures between the cervical aspects of the denture teeth and peripheral denture borders to record functional tissue interactions with these denture surfaces. The wax trial dentures carried impression material into the oral cavity and the patient was instructed to close, purse the lips as in sucking, and then swallow. Once completed, excess impression material was removed and the trial dentures were invested and processed using conventional methods.

With advances in material science and the development of innovative clinical techniques, prosthodontic advantages of the neutral zone technique may be incorporated into

any complete denture treatment. A detailed protocol of recommended procedures and materials for accomplishing the modern neutral zone procedure follows. Though particularly indicated for patients suffering from severe residual ridge atrophy and/or chronically reduced occlusal vertical dimension, the procedures discussed here may be used during most edentulous therapies, including those incorporating dental implants.

TECHNIQUE

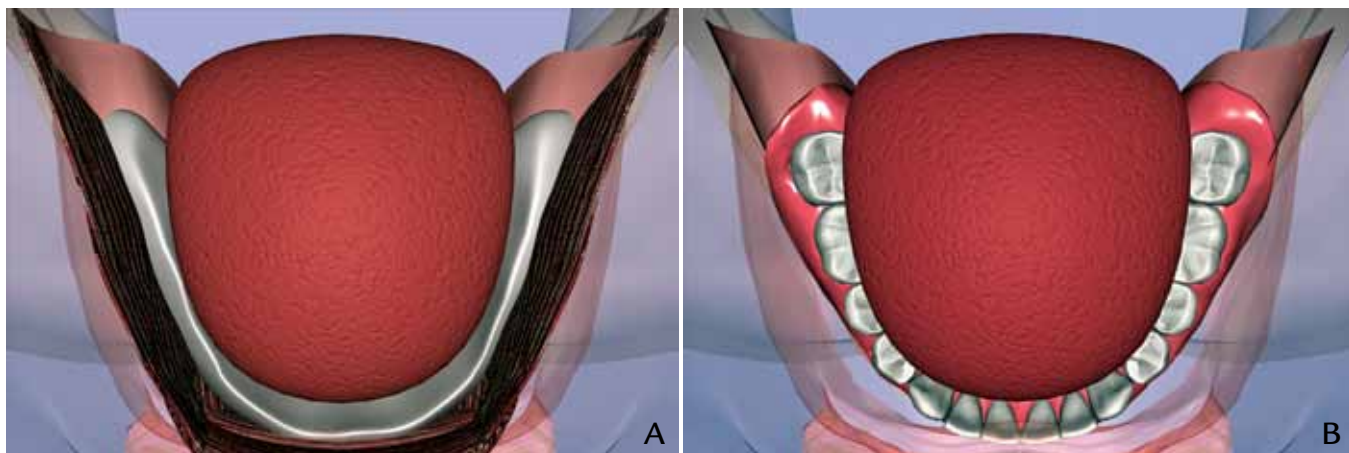
1. Fabricate the mandibular neutral zone record base and rim, constructing the mandibular record base using conventional methods.⁴⁷ Apply hot red modeling plastic impression compound (Impression Compound; Kerr Corp, Orange, Calif) to the record base to facilitate adhesion of the rim. In a water bath set to 140°F,

warm 2 sticks of grey and 1 stick of green modeling plastic impression compound (Impression Compound; Kerr Corp), knead the material thoroughly, and adapt it to the record base, forming a recording rim. Seal the edges of the recording rim to the record base using a heated spatula. Place the completed record base and recording rim in the water bath for approximately 2 minutes in preparation for the clinical procedure.

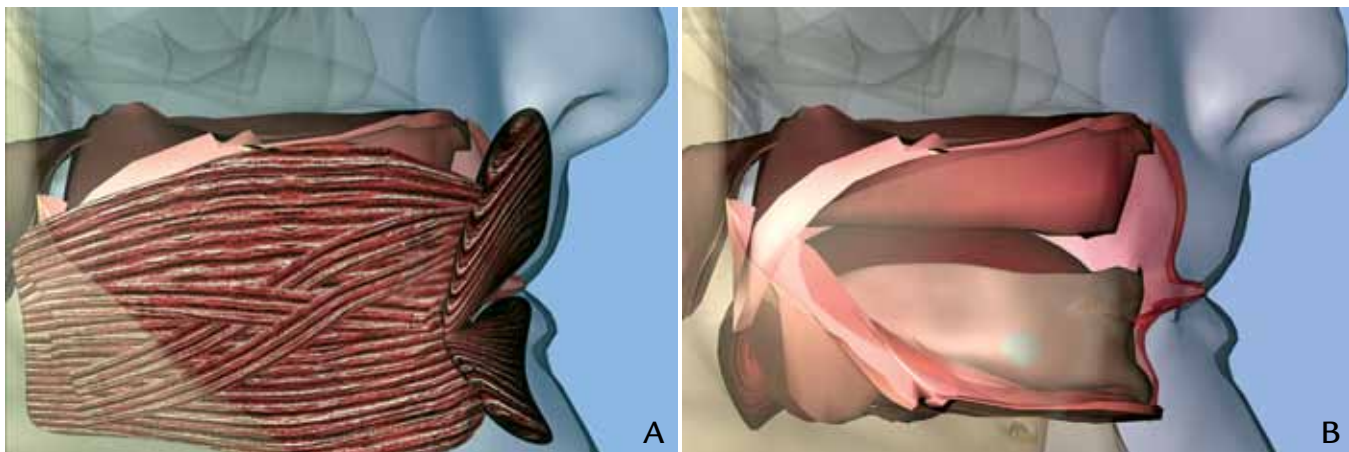
2. Do not use a maxillary record base during clinical registration of the mandibular neutral zone, as eliminating the maxillary record base and rim avoids compressive interferences if occlusal contacts are encountered during this functional recording procedure. Since the swallowing maneuver is used during registration of the neutral zone, exercise care for patients wearing complete dentures with substantially reduced occlusal vertical

dimension. Note that habitually patients with decreased occlusal vertical dimension typically produce horizontally excessive and vertically reduced neutral zone records. Prior to registering the mandibular neutral zone, re-establish an appropriate vertical jaw relationship, and deprogram muscles responsible for mandibular posture. Use effective clinical deprogramming techniques that have been previously described elsewhere⁴⁸ for complete denture patients.

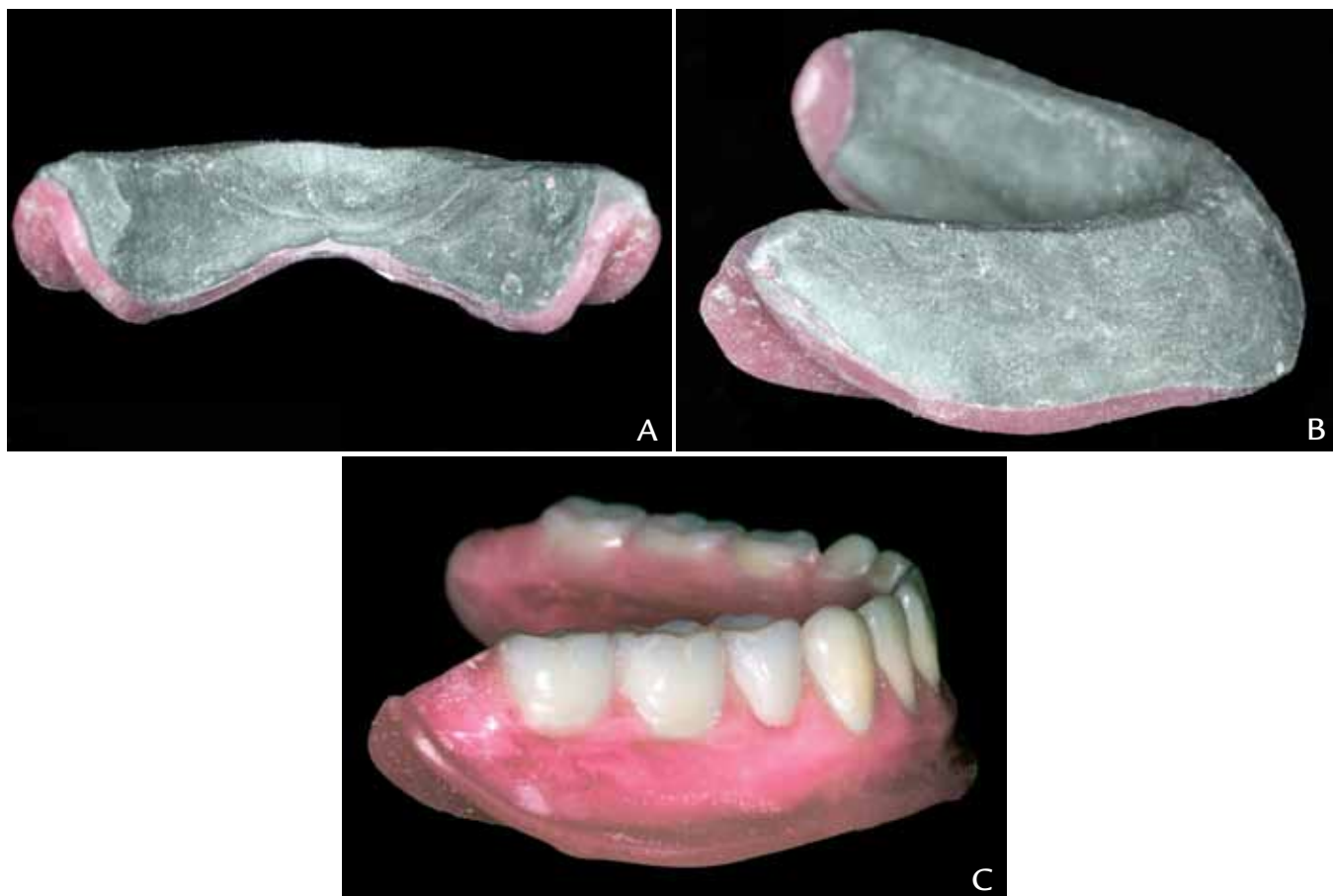
3. Remove the base and rim from the water bath and quickly place intraorally. Instruct the patient to swallow. Next, provide a cup of warm water to the patient and instruct the patient to sip and swallow. Have the patient repeat this sip and swallow exercise several times. Note how the muscles of the cheeks and lips move inward while the muscles of the tongue move outward (Figs. 1 and 2).



1 A, Relationship between muscles of face, neutral zone record, and tongue. B, Teeth of definitive denture placed within neutral zone.



2 A, Anatomic depiction of overlying buccinator and orbicularis oris muscles. B, Underlying mandibular neutral zone record.



3 Completed mandibular neutral zone record from: A, lingual, and B, lateral views. C, Note neutral zone's influence on mandibular denture tooth arrangement.

Also, note that this coordinated muscle activity plastically shapes the rim to form the neutral zone. Observe the resulting volume of the neutral zone record as it defines the area in which the denture teeth will be placed.

4. When the neutral zone record has cooled and hardened, remove and inspect the record for accuracy and completeness (Fig. 3). If necessary, repeat the procedure to ensure proper recording of the entire neutral zone. Eliminate excess modeling plastic impression compound displaced superior to the intended occlusal plane during the recording procedure and, if necessary, repeat the recording process, beginning with the warm water bath.

5. To develop the lingual neutral zone index, seat the neutral zone record on the mandibular definitive cast. Prepare laboratory putty (Poly V Putty; Accurate Set, Inc, Newark, NJ) to a workable consistency and adapt it into the tongue space of the neutral

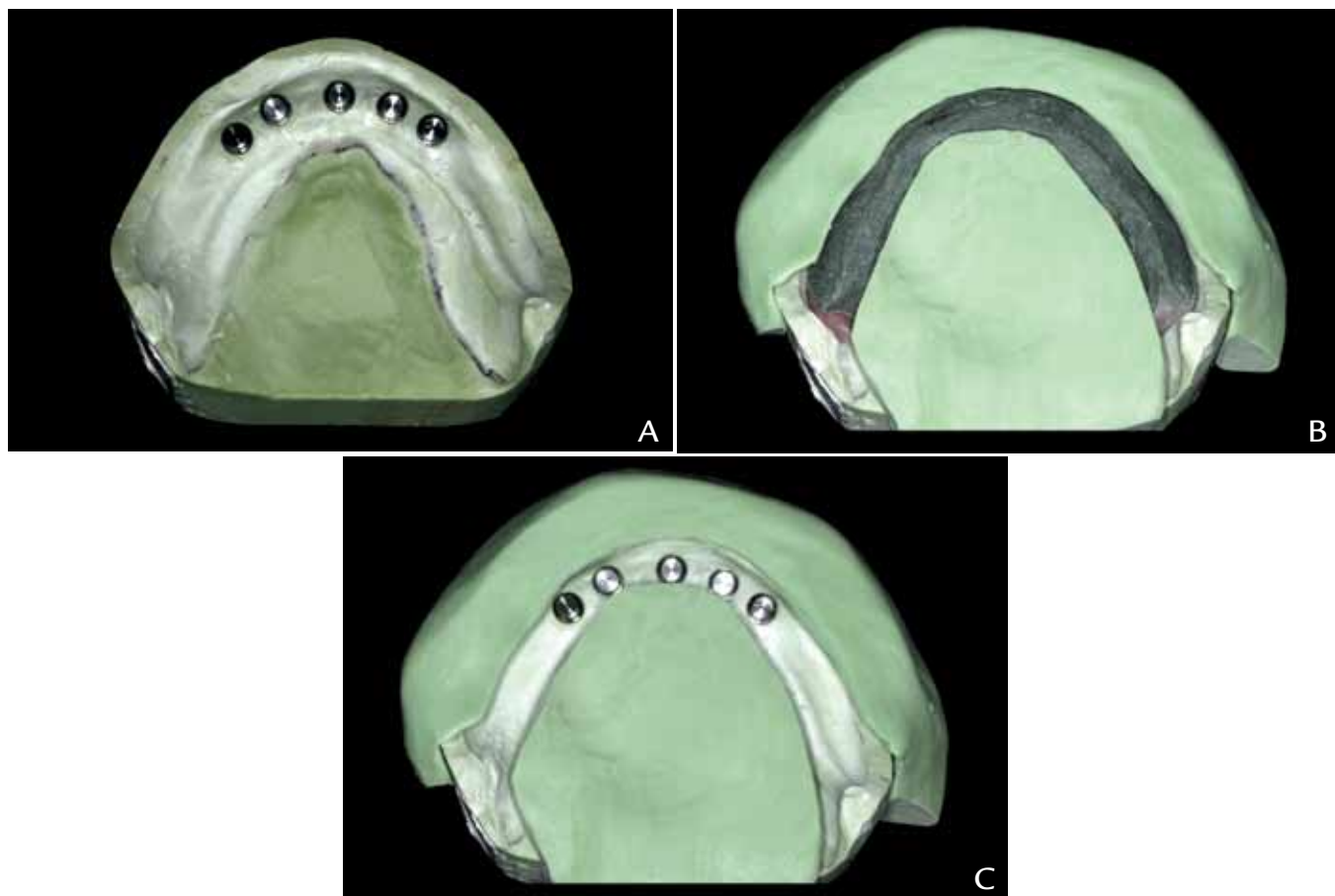
zone record. Mold the putty so that it: (a) completely fills the tongue space; (b) adapts accurately to the lingual contours of the neutral zone record; (c) is level with the occlusal plane of the record; and (d) extends over the posterior land area of the cast. Select the occlusal plane template that will be used during denture tooth arrangement. Position the template over the tongue space, and form the putty to the template to facilitate its placement during denture tooth arrangement.

6. Develop the facial index. Adapt a rope of laboratory putty (Poly V Putty; Accurate Set, Inc) along the facial contours of the neutral zone record. Mold the putty so that it: (a) completely and accurately captures the facial contours of the neutral zone record; (b) is level with the occlusal plane of the record; and (c) extends over the land area of the cast. Once polymerized, remove both the lingual and facial indices and ensure that

they can be replaced accurately and securely on the cast in the absence of the neutral zone record (Fig. 4).

7. Arrange maxillary anterior teeth and maxillary first premolars using conventional methods.⁴⁹ Fabricate a new mandibular record base in the same manner as previously done. Arrange the mandibular anterior teeth on the new record base so that desired relationships are established with the maxillary anterior teeth and so that the mandibular teeth fall within the neutral zone, as dictated by the facial and lingual indices. Arrange the mandibular posterior denture teeth so that all posterior teeth contact the lingual index and all posterior teeth contact the desired occlusal plane template. Complete the denture tooth arrangement by positioning maxillary teeth using conventional methods.⁴⁹

8. In preparation for external impressions used to define denture polished surface contours within the neutral zone, carefully remove all



4 A, Definitive mandibular cast. B, Neutral zone record and VPS indices on cast. C, Neutral zone indices and definitive cast in absence of neutral zone record.

baseplate wax apical to denture teeth on the facial and lingual aspects of the mandibular trial denture and the facial and palatal aspects of the maxillary trial denture. Practice required orofacial movements with the patient prior to making impressions. Note that the prescribed sequence of movements will be repeated several times during the impression procedure.

9. Apply vinyl polysiloxane (VPS) adhesive (Caulk Tray Adhesive; Dentsply Caulk, Milford, Del) and low-viscosity VPS (Aquasil Ultra LV Fast Set; Dentsply Caulk) onto facial aspects of the maxillary trial denture where wax was removed. Place the trial denture intraorally, being careful not to displace impression material. Use cheek retractors (Columbia Cheek Retractors; Hu-Friedy Mfg Co, Inc, Chicago, Ill) to aid in the placement of trial dentures, if desired. Instruct the patient to pucker the lips forward, smile broadly, open the mouth, and move the mandible from

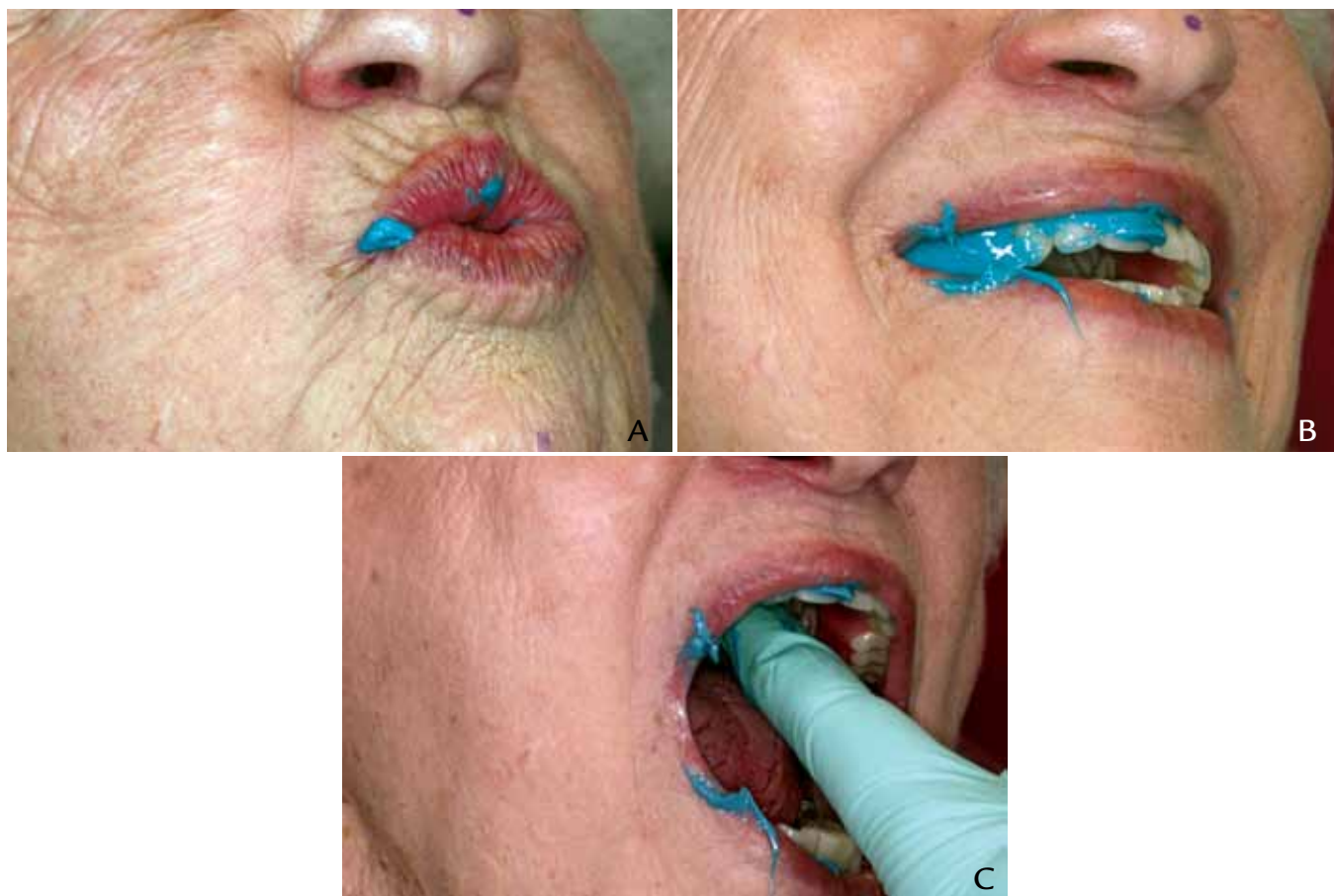side to side. Have the patient repeat these movements several times (Fig. 5). Upon polymerization of the impression material, remove the trial denture and evaluate the impression. Examine denture flange dimensions and extensions in relation to impression contours. Adjust record base and wax contours accordingly. Trim excess impression material from the trial denture and carefully eliminate all material covering the denture teeth (Fig. 6).

10. Apply VPS adhesive and low-viscosity VPS onto palatal aspects of the maxillary trial denture in areas of wax removal. Place the trial denture and instruct the patient to sip water and swallow, perform sibilant phonetics, and perform fricative phonetics. Have the patient repeat these exercises several times. Upon material polymerization, remove the trial denture and examine the impression for completeness. Trim excess impression material from the trial denture, and

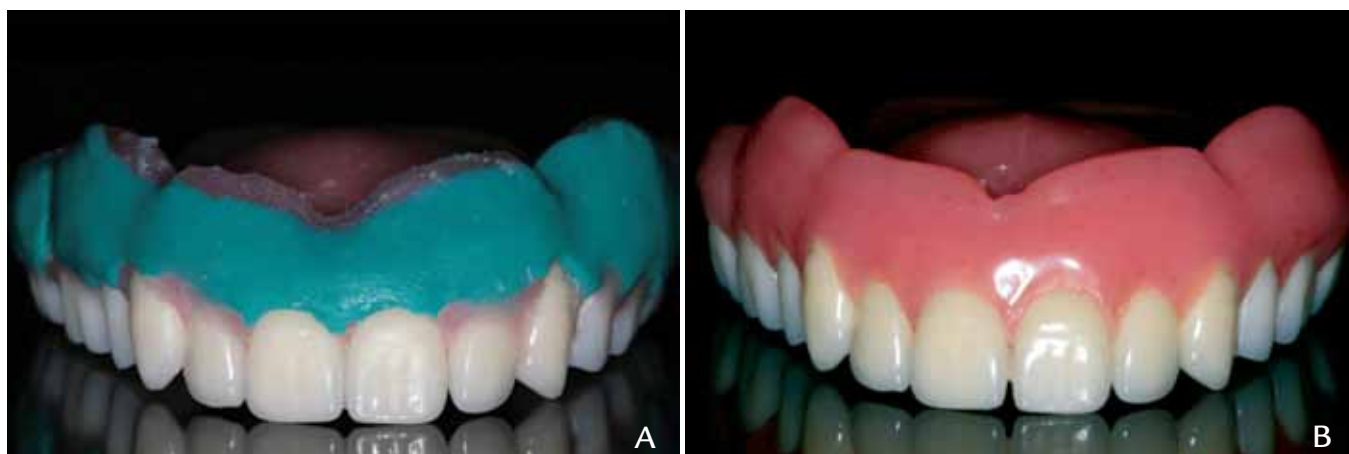
carefully eliminate all material covering the denture teeth.

11. Apply VPS adhesive (Caulk Tray Adhesive; Dentsply Caulk) and low-viscosity VPS (Aquasil Ultra LV Fast Set; Dentsply Caulk) onto facial aspects of the mandibular trial denture, and carefully place the trial denture into the patient's mouth. Instruct the patient to pucker the lips forward, smile broadly, move the mandible into protrusive posture, and then move the mandible from side to side. Have the patient repeat these movements several times. Remove the trial denture and evaluate the impression. Examine denture flange dimensions and extensions. Adjust record base and wax contours accordingly. Trim excess impression material and carefully eliminate all material covering the denture teeth.

12. Finally, make an external impression along the mandibular lingual flanges. Apply VPS adhesive (Caulk Tray Adhesive; Dentsply Caulk) and



5 During maxillary external impression, patient is required to: A, pucker lips forward; B, provide full smile; C, open mouth wide.



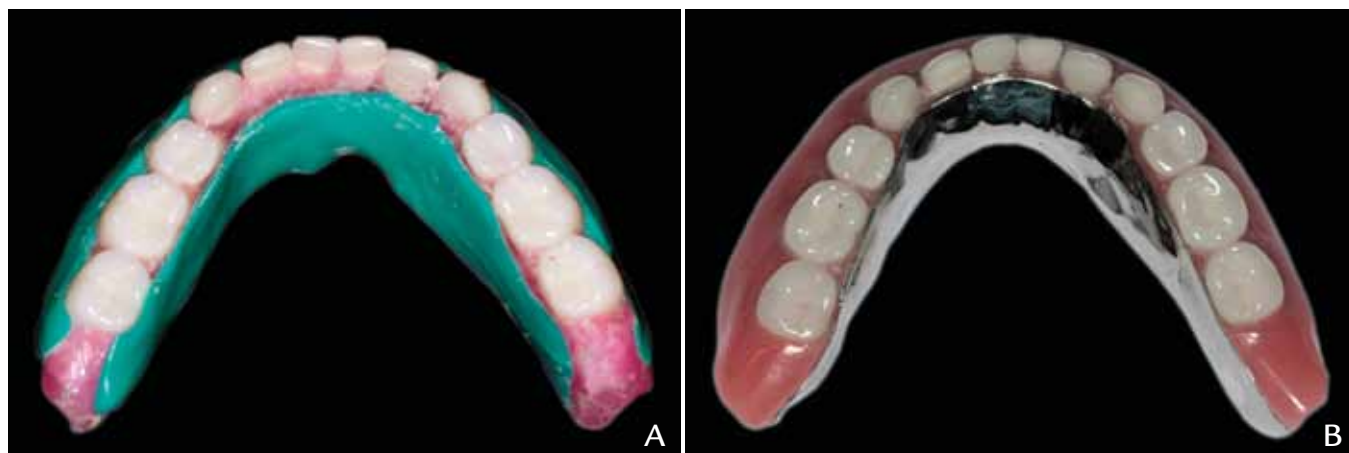
6 Denture polished surface contour represented by: A, maxillary facial external impression, and B, definitive maxillary complete denture.

low-viscosity VPS (Aquasil Ultra LV Fast Set; Dentsply Caulk) along the lingual flanges of the mandibular trial denture. Place the trial denture and instruct the patient to sip water and swallow several times, extend the tongue and move it from side to side,

and, finally, lick the upper and lower lips. Have the patient repeat these movements until the impression material polymerizes. Remove the trial denture and examine denture flange dimensions and extensions. Adjust record base and wax contours, and then

trim excess impression material from the trial denture. Carefully eliminate all material covering the denture teeth (Fig. 7).

13. Invest, process, finish, and polish the dentures using conventional methods.^{50,51}



7 Denture polished surface contour represented by: A, mandibular facial and lingual external impressions, and B, definitive mandibular complete overdenture.

DISCUSSION

Techniques described here are intended to emphasize and illustrate the clinical value of recording the physiologic dynamics of oral and perioral muscle function and of using this information to develop complete denture contours and denture tooth positions. Arranging artificial teeth within the neutral zone achieves 2 important objectives: (1) prosthetic teeth do not interfere with normal muscle function; and (2) normal oral and perioral muscle activity imparts force against the complete dentures that serves to stabilize and retain the prostheses rather than cause denture displacement.³⁷ The neutral zone method typically locates posterior denture teeth slightly facially, when compared to teeth arranged over the crest of the residual ridge.⁵²

Using the neutral zone to arrange posterior teeth takes advantage of the stabilizing potential of existing muscle conditions. This physiologically based complete denture design concept has been shown to be especially effective for mandibular removable prostheses. It is particularly remarkable to observe neutral zones recorded for patients affected by neuromuscular decline or gross dysfunction; for example, patients of advancing age and/or long-term edentulism with decreasing facial muscle tonicity,⁵³ anatomic deformity or insufficiency, such as in post-cancer oral surgical resections,⁵⁴⁻⁵⁷

or those suffering facial neuromuscular deficit secondary to cerebral vascular accidents or Parkinson's disease.⁵⁸ Conventional methods used for these patients result in denture contours that may not facilitate prosthesis stability against expected oral and perioral muscle function. Conversely, the fabrication of denture contours to harmonize with aberrant neutral zone dimensions, characteristic of these compromised patients, results in increased denture stability and improved oral function.

A variety of conditions affecting tongue and facial musculature in the edentulous state can be registered using neutral zone and external impression techniques. It is particularly interesting to compare denture polished surface contours developed using conventional waxing methods to those resulting from the physiologically based clinical registration methods described in this article. Hand-waxed denture base contours typically incorporate concavities along facial prosthetic surfaces. More frequently, however, contours resulting from physiologically molded external impressions yield generalized convexities along the facial surfaces of both maxillary and mandibular dentures. This is particularly true in molar regions and for patients of advancing age with decreasing facial muscle tonicity. Considering potential stabilizing effects associated with the neutral zone technique, it has been suggested that

concave facial denture flange contours are physiologically inappropriate and contraindicated with respect to optimal prosthesis stability.^{59,60}

A thorough understanding of the anatomy and physiology of structures that impact sound complete denture fabrication and function is important for successful treatment of edentulous patients. Use of the neutral zone method to identify and register the anatomy and physiology that impact prosthesis stability may result in improved prosthodontic therapy for patients.

SUMMARY

This article presents historical perspectives on the appropriate arrangement of denture teeth and considerations for the contouring of complete denture polished surfaces. Additionally, a modern clinical technique intended for the physiologic registration of optimal denture tooth positions and denture base contours is discussed. Clinicians may choose to incorporate this technique into the routine prosthodontic management of edentulous patients.

REFERENCES

1. Atwood DA. Reduction of residual ridges: a major oral disease entity. *J Prosthet Dent* 1971;26:266-79.
2. Tallgren A. The continuing reduction of the residual alveolar ridges in complete denture wearers: a mixed-longitudinal study covering 25 years. *J Prosthet Dent* 1972;27:120-32.

3. Weinberg LA. Tooth position in relation to the denture base foundation. *J Prosthet Dent* 1958;8:398-405.
4. Fish EW. Principles of full denture prosthesis. London: John Bale, Sons & Danielsson, Ltd; 1933. p. 1-8.
5. Wright CR. Evaluation of the factors necessary to develop stability in mandibular dentures. *J Prosthet Dent* 1966;16:414-30.
6. Brill N, Tryde G, Cantor R. The dynamic nature of the lower denture space. *J Prosthet Dent* 1965;15:401-18.
7. Sheppard IM. Denture base dislodgement during mastication. *J Prosthet Dent* 1963;13:462-8.
8. Kuebker WA. Denture problems: causes, diagnostic procedures, and clinical treatment. I. Retention problems. *Quintessence Int Dent Dig* 1984;15:1031-44.
9. Pound E. Lost-fine arts in the fallacy of the ridges. *J Prosthet Dent* 1954;4:6-16.
10. Fahmy FM, Kharat DU. A study of the importance of the neutral zone in complete dentures. *J Prosthet Dent* 1990;64:459-62.
11. Wright CR, Swartz WH, Godwin WC. Mandibular denture stability - a new concept. *Ann Arbor: The Overbeck Co*; 1961. p. 29-41.
12. Schole ML. Management of the gagging patient. *J Prosthet Dent* 1959;9:578-83.
13. Morstad AT, Peterson AD. Postinsertion denture problems. *J Prosthet Dent* 1968;19:126-32.
14. Means CR, Flenniken IE. Gagging--a problem in prosthetic dentistry. *J Prosthet Dent* 1970;23:614-20.
15. Kuebker WA. Denture problems: causes, diagnostic procedures, and clinical treatment. III/IV. Gagging problems and speech problems. *Quintessence Int Dent Dig* 1984;15:1231-8.
16. Watt DM. Tooth positions on complete dentures. *J Dent* 1978;6:147-60.
17. Watt DM, MacGregor AR. Designing complete dentures. 2nd ed. Bristol: IOP Publishing Ltd; 1986. p. 1-31.
18. Robinson SC. Physiological placement of artificial anterior teeth. *J Can Dent Assoc (Tor)* 1969;35:260-6.
19. Payne AG. Factors influencing the position of artificial upper anterior teeth. *J Prosthet Dent* 1971;26:26-32.
20. Murray CG. Re-establishing natural tooth position in the edentulous environment. *Aust Dent J* 1978;23:415-21.
21. Rahn AO, Heartwell CM Jr. Textbook of complete dentures. 5th ed. Philadelphia: Lippincott, Williams & Wilkins; 1993. p. 352-6.
22. Hardy IR. Technique for use of non-anatomic acrylic posterior teeth. *Dent Digest* 1942;48:562-6.
23. Lang BR, Razzoog ME. A practical approach to restoring occlusion for edentulous patients. Part II: Arranging the functional and rational mold combination. *J Prosthet Dent* 1983;50:599-606.
24. Gysi A. Practical application of research results in denture construction. *J Am Dent Assoc* 1929;16:199-223.
25. Sharry JJ. Complete denture prosthodontics. 3rd ed. New York: McGraw-Hill; 1974. p. 241-65.
26. Pound E. Esthetic dentures and their phonetic values. *J Prosthet Dent* 1951;1:98-111.
27. Pound E, Murrell GA. An introduction to denture simplification. Phase II. *J Prosthet Dent* 1973;29:598-607.
28. Roraff AR. Arranging artificial teeth according to anatomic landmarks. *J Prosthet Dent* 1977;38:120-30.
29. Halperin AR, Graser GN, Rogoff GS, Plekavich EJ. Mastering the art of complete dentures. Chicago: Quintessence; 1988. p. 125.
30. Sears VH. Principles and technics for complete denture construction. St. Louis: Mosby; 1949. p. 103-8, 279-80.
31. DeVan MM. The concept of neurocentric occlusion as related to denture stability. *J Am Dent Assoc* 1954;48:165-9.
32. el-Gheriani AS. A new guide for positioning of maxillary posterior denture teeth. *J Oral Rehabil* 1992;19:535-8.
33. Lammie GA. Aging changes and the complete lower denture. *J Prosthet Dent* 1956;6:450-64.
34. Martone AL. The phenomenon of function in complete denture prosthodontics. Clinical applications of concepts of functional anatomy and speech science to complete denture prosthodontics. Part VIII. The final phases of denture construction. *J Prosthet Dent* 1963;13:204-28.
35. Campbell DD. Full denture prosthesis. St. Louis: Mosby; 1924. p. 82-4.
36. Zarb GA, Bolender CL, Hickey JC, Carlsson GE. Boucher's prosthodontic treatment for edentulous patients. 10th ed. St. Louis: Mosby; 1990. p. 363.
37. Beresin VE, Schiesser FJ. The neutral zone in complete dentures. *J Prosthet Dent* 1976;36:356-67.
38. Fish EW. Using the muscles to stabilize the full lower denture. *J Am Dent Assoc* 1933;20:2163-9.
39. Matthews E. The polished surfaces. *Br Dent J* 1961;111:407-11.
40. Grant AA, Johnson W. An introduction to removable denture prosthetics. Edinburgh: Churchill Livingstone; 1983. p. 24-8.
41. Wright SM. The polished surface contour: a new approach. *Int J Prosthodont* 1991;4:159-63.
42. Schlosser RO. Complete denture prosthesis. Philadelphia: WB Saunders; 1939. p. 183-90.
43. Roberts AL. The effects of outline and form upon denture stability and retention. *Dent Clin North Am* 1960;4:293-303.
44. Beresin VE, Schiesser FJ, editors. Neutral zone in complete and partial dentures. 2nd ed. St. Louis: Mosby; 1979. p. 15,73-108, 158-83.
45. Martone AL. The phenomenon of function in complete denture prosthodontics. Clinical applications of concepts of functional anatomy and speech science to complete denture prosthodontics. Part VI. The diagnostic phase. *J Prosthet Dent* 1962;12:817-34.
46. McDonald GT, Larsen HD. Laboratory procedures for the neutral zone denture technique. *Quintessence Dent Technol* 1985;9:287-90.
47. Rudd KD, Morrow RM. Baseplates and occlusion rims. In: Dental laboratory procedures: complete dentures, volume I. 2nd ed. Morrow RM, Rudd KD, Rhoads JE, editors. St. Louis: Mosby; 1986. p. 90-146.
48. Massad JJ, Connolly ME, Rudd KD, Cagna DR. Occlusal device for diagnostic evaluation of maxillomandibular relationships in edentulous patients: a clinical technique. *J Prosthet Dent* 2004;91:586-90.
49. Smith RA, Cavalcanti AA, Wolfe HE. Arranging and articulating artificial teeth. In: Dental laboratory procedures: complete dentures, volume I. 2nd ed. Morrow RM, Rudd KD, Rhoads JE, editors. St. Louis: Mosby; 1986. p. 223-75.
50. Rudd KD, Morrow RM, Feldmann EE, Espinoza AV, Gorney C. Waxing and processing. In: Dental laboratory procedures: complete dentures, volume I. 2nd ed. Morrow RM, Rudd KD, Rhoads JE, editors. St. Louis: Mosby; 1986. p. 276-311.
51. Rudd KD, Morrow RM, Espinoza AV, Leachman JS. Finishing and polishing. In: Dental laboratory procedures: complete dentures, volume I. 2nd ed. Morrow RM, Rudd KD, Rhoads JE, editors. St. Louis: Mosby; 1986. p. 312-38.
52. Boucher CO. Complete denture prosthodontics - The state of the art. *J Prosthet Dent* 1975;34:372-83.
53. Fahmy FM. The position of the neutral zone in relation to the alveolar ridge. *J Prosthet Dent* 1992;67:805-9.
54. Ries GE. The neutral zone as applied to oral and facial deformities. In: Neutral zone in complete and partial dentures. 2nd ed. Beresin VE, Schiesser FJ, editors. St. Louis: Mosby; 1978. p. 208-20.
55. Ohkubo C, Hanatani S, Hosoi T, Mizuno Y. Neutral zone approach for denture fabrication for a partial glossectomy patient: a clinic report. *J Prosthet Dent* 2000;84:390-3.
56. Pekkan G, Hekimoglu C, Sahin N. Rehabilitation of the marginal mandibulectomy patient using a modified neutral zone technique: a case report. *Braz Dent J* 2007;18:83-6.
57. Kokubo Y, Fukushima S, Sato J, Seto K. Arrangement of artificial teeth in the neutral zone after surgical reconstruction of the mandible: a clinical report. *J Prosthet Dent* 2002;88:125-7.
58. Lloyd PM. Complete-denture therapy for the geriatric patient. *Dent Clin North Am* 1996;40:239-54.
59. Raybin NH. The polished surface of complete dentures. *J Prosthet Dent* 1963;13:236-9.
60. Devlin H. Complete dentures: a clinical manual for the general dental practitioner. New York: Springer-Verlag; 2002. p. 55-6.

Corresponding author:

Dr David R. Cagna
University of Tennessee Health Science Center
College of Dentistry
Department of Restorative Dentistry
875 Union Ave
Memphis, TN 38163
Fax: 901-448-1294
E-mail: dcagna@utmem.edu

Acknowledgements

The authors wish to acknowledge the valued assistance of Ron Johnson, CDT, from Stern Empire Dental Laboratory in Houston, Tex, in all dental laboratory technical aspects of this article. Without the reliable, skilled, and highly professional participation of talented dental technicians, such as Mr Johnson, the prosthodontic procedure discussed here would be impossible.

Copyright © 2009 by the Editorial Council for
The Journal of Prosthetic Dentistry.